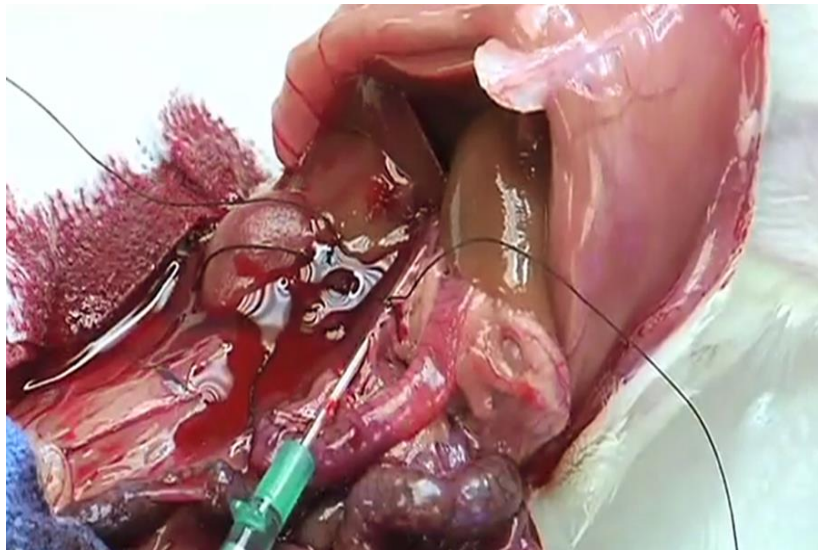
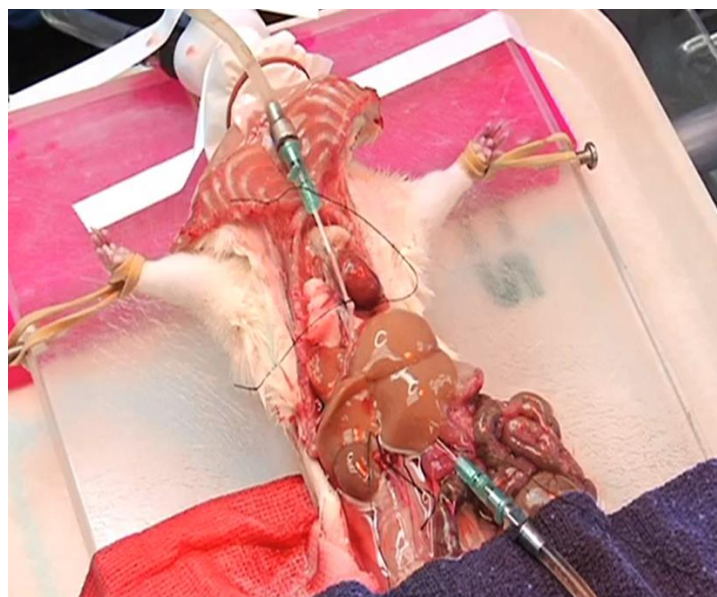


The liver were initially perfused with Krebs- bicarbonate buffer (pH=7.2) for 10 min. When the lobes of liver begin swelling, a cut was made at lower IVC (Figure 2.5).



**(Figure 2.5): Cannulation the portal vein with 16 GA catheter and perfusion with Krebs buffer, then cut the lower inferior vena cava.**

Then exsanguination of the liver will be facilitated by inserting tubing into the IVC through the right atrium and the ligature around the IVC was tied very well to avoid leakage (Figure 2.6).



**(Figure 2.6): Exsanguination of the liver will be facilitated by inserting tubing into the IVC through the right atrium.**